

MRI Screening High Risk Women

The Gadolinium Controversy

Dr Jane Reasbeck MBBS FRANZCR

Radiologist

VMO BreastScreen QLD and Wesley Breast Clinic

Dr Elizabeth Evans MBBS MFM(Clin)

Research Co-ordinator/Data manager

Wesley Breast Clinic

What is Gadolinium?

Rare earth metal, naturally occurring in certain ores.

Heavy metal - Lanthanide series

Symbol Gd - Atomic Number 64.

Paramagnetic Property – due to presence of 7 unpaired electrons.

Gadolinium clinical use in MRI

- * 1984 Gadolinium found to provide enhancement of relaxation rate.
- * 1988 Gadolinium Agents introduced into clinical practice.
- * As of 2016 an estimated 200-350 million + doses have been administered worldwide.

Gadolinium Excretion

- * Plasma half-life 1.6 hours.
- * With a half life this short 99.99% should be eliminated in 24hours.
- * But only 91% is excreted in 24hours.
- * Therefore about 10% of the dose is “sequestered” and presumed to be excreted more slowly.

(Weinmann et al *Physiol Chem Phys Med NMR* 1984;16:167,1984)

2006

Nephrogenic Systemic Fibrosis

Gadolinium - a specific trigger for the development of nephrogenic fibrosing dermopathy and nephrogenic systemic fibrosis

(Grobner et al. *Nephrol Dial Transplant* 2006;21:1104-1108)

Nephrogenic Systemic Fibrosis NSF

- * Widespread and life threatening process predominantly involving skin and subcutaneous tissues.
- * May progress rapidly with severe joint contractures.
- * Critical factors in its genesis are severe renal failure and IV administration of gadolinium, especially linear agents.

Gadolinium retention in bone


Studies on excised femoral heads of patients undergoing hip replacement:

Gadolinium was found in the hip bones of patients with normal renal function.

(Gibby et al. *Invest Radiol* 2004;39:138-142.)

Anomalous high levels of Gd in bone up to 8 years after administration of chelated Gd.

(Darrah et al. *Metallomics* 2009; 6:479-488.)

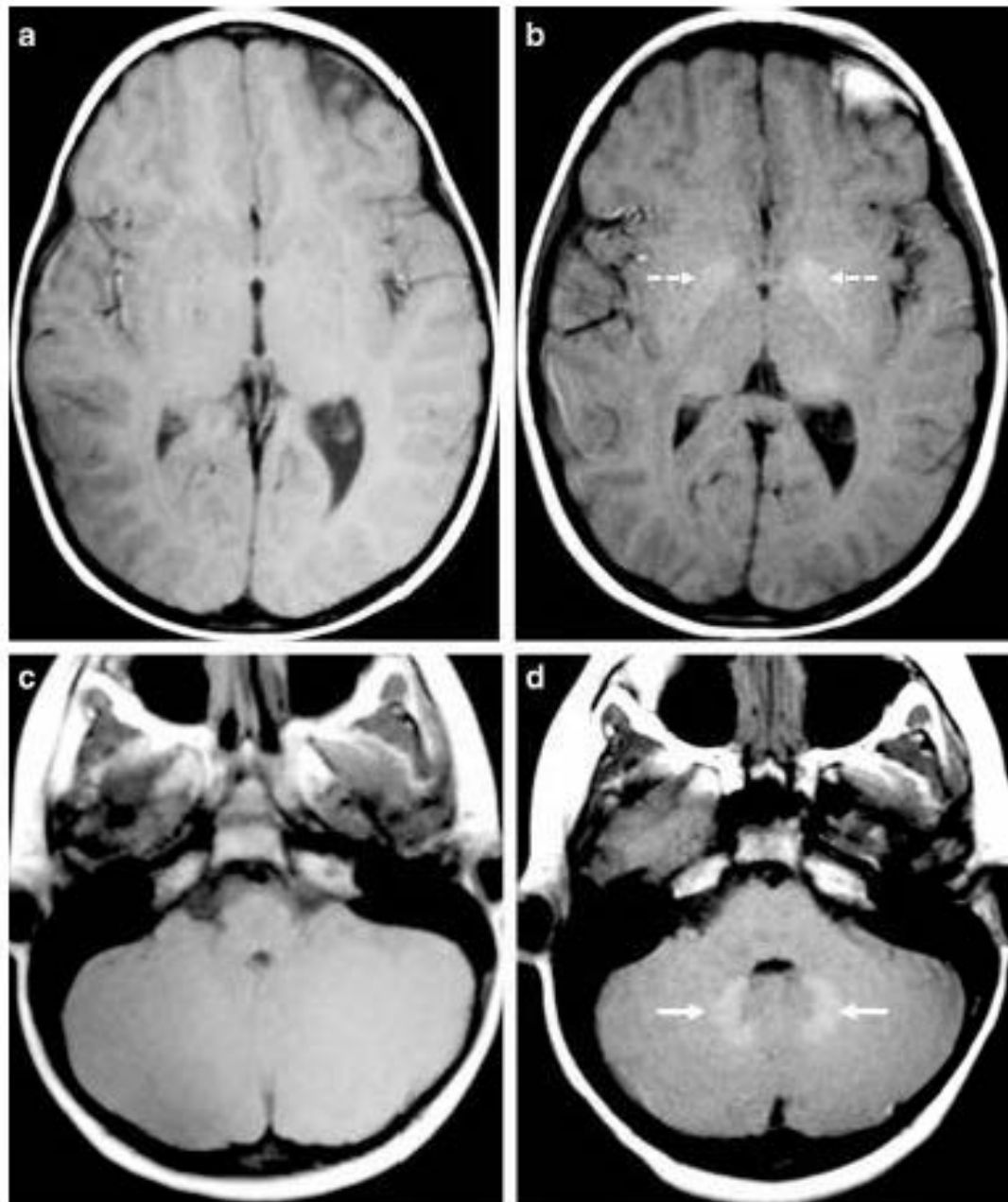


So, It's hit the fan then.

Kanda et al reported an observation. Subsequently, other research has confirmed this observation is due to gadolinium.

There have been no reliable reports of specific neurologic deficit in relation to the observation of cerebral accumulation of Gadolinium.

Fig. 1 Representative precontrast unenhanced T1-weighted 2-D fast spin echo images from gadolinium-based contrast agent (GBCA) patient 9 (female) (a, c) show comparison images from the patient's first GBCA MRI examination, at the age of 3.9 years and images (b, d) from the patient's most recent (23rd) GBCA MRI examination, approximately 6.7 years later at the age of 10.6 years. Image appearances of the dentate nucleus (*solid arrows*) and globus pallidus (*dashed arrows*) structures are typically isointense with surrounding gray and white matter at the baseline and become more prominent with repeated GBCA administration



Publications on gadolinium

- * Up to 2014 - sporadic publications, increasing in 2015.
- * 2016 - At least 30 major articles published. Many basic science papers as well as clinical papers. December issue of MRI journal completely devoted to gadolinium.
- * 2017---2018, wait and see.

Gadolinium in Humans: A family of Disorders

Semelka et al. AJR
2016;207:229-233

“Gadolinium Storage Condition”

“Gadolinium Deposition Disease”

Gadolinium Storage Condition

Histologically proven presence of
Gadolinium in tissue.

Gd has been found in brain and bone at autopsy of patients with normal renal function.

(McDonald et al *Radiology* 2015;275:772-82

Kanda et al *Radiology* 2015;276:228-32)

Gd has been found in skin biopsy of patient with normal renal function who had 61 contrast MRIs over 11 years and had severe joint contractures of unknown etiology.

(Roberts *Invest Radiol* 2016;51(5):280-289)

What are these symptoms?

- * Subcutaneous skin thickening “glove and stocking” distribution.
- * Skin Plaques (Gathings et al *JAMA Dermatol* 2015;151(3):316-319)
- * Painful tendons and ligaments
- * Excruciating peripheral pain. Torso may be affected.
- * Clouded mentation (“brain fog”).

Burke *Magn Reson Imaging* 2016;34(8):1078-80

Sharon Williams

"The Lighthouse Project"

- * Initial letter to Commissioner U.S. Food and Drug Administration 2012 with follow-up in 2016. Scientific discussion, supported by 187 references.
- * www.GadoliniumToxicity.com
- * Not promulgating pseudo-science but scientifically looking for answers for a group of people who believe they suffered symptoms after GBCA administration.
- * Publication of scientific papers on website, with full recognition of their limitations.

Why use gadolinium in Breast MRI?

In symptomatic women, GBCA MRI allows detection of lesions which would otherwise go undiagnosed.

BUT – Screening breast MRI is a unique situation - the only instance in radiological practice where contrast MRI is used repeatedly in screening people who are well.

Should we be concerned?

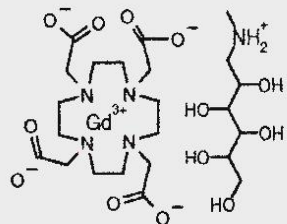
Yes!

What should we do?

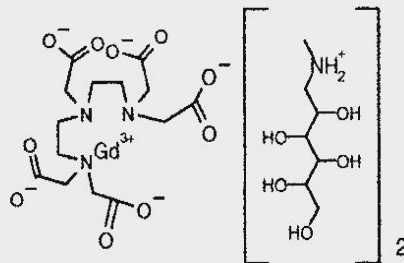
Macrocyclic

Open chain

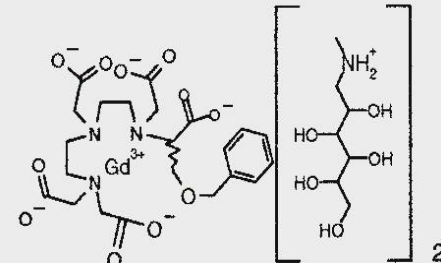
ionic



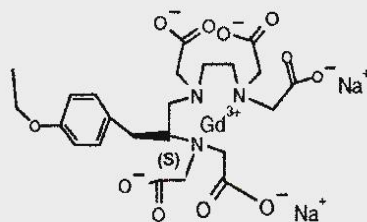
Gd-DOTA, Dotarem®



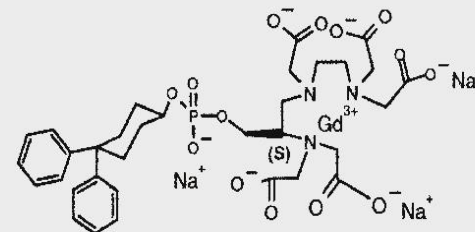
Gd-DTPA, Magnevist®



BOPTA, MultiHance®

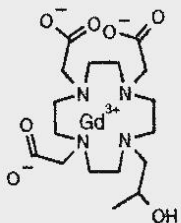


Gd-EOB-DTPA, Primovist®

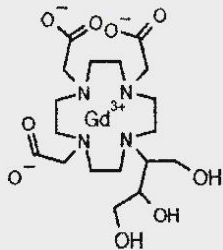


MS325, Vasovist®

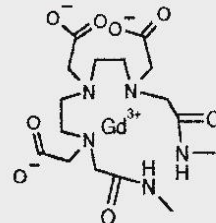
Non ionic



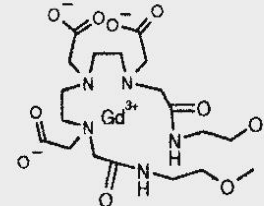
Gd-HP-DO3A, ProHance®



Gd-BT-DO3A, Gadovist®



Gd-DTPA-BMA, Omniscan®



Gd-DTPA-BMEA, OptiMARK®

Patient Sub-selection

- * Genetic Testing
- * Breast Density Measurement
- * Patient Age at Presentation
- * Patient Anxiety

Informed Consent

- * This is not optional, but in many practices the information given about Gadolinium is inadequate.
- * This is not done by the radiologist who will be considered responsible for the administration of contrast.
- * Given the multiple doses a woman might receive for screening purposes, and the resultant Gadolinium accumulation, this issue should be taken seriously.

Sir Muir Gray, former director of the UK National

Screening Committee

" All screening programmes do harm; some do good as well, and, of these, some do more good than harm at reasonable cost."

Curr Oncol.2015J;22(3):220-229

THE END

